




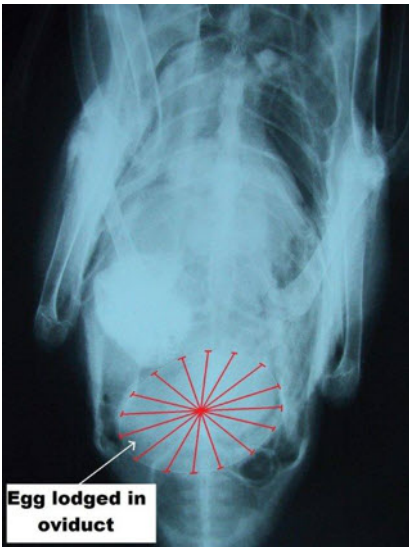
Egg-bound Duck



"You'll never guess what happened to me!"

I can imagine that there are quite a few readers who have "had their fill" of eggs over the last couple of weeks but spare a thought for one of our most recent patients.

Her owners had become aware that she wasn't quite right. She had appeared uncomfortable and hadn't been feeding properly. My colleague Aga confirmed her clinical suspicions of "egg bound" with a fine detail x-ray.

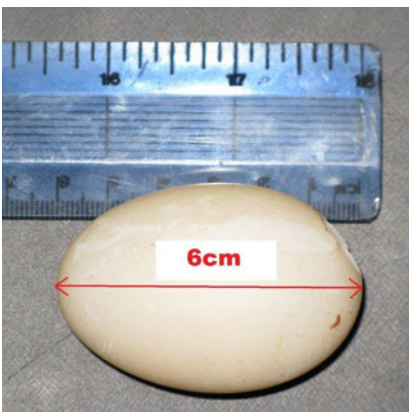


Treatment with calcium supplementation and pain relief was initiated but was unsuccessful. Lubrication and digital manipulation also proved fruitless. The situation looked bleak.

The oviduct, which is the muscular organ in which the eggs develop and from which they are subsequently ejected had become twisted rendering removal apparently impossible.

Then, Aga had an inspired moment. The patient was anaesthetised and the oviduct was exteriorised by causing a prolapse. The egg was then surgically removed, the oviduct was sewn back together and then the prolapse was replaced.

To all intents and purposes the egg was delivered by a caesarian, an absolute first at Fairfield and our poultry patients are hopingthe last!



Terry Dunne BVMS, Cert SAO, MRCVS

This article is available on the Fairfield Veterinary Centre web site at www.fairfield-vets.co.uk