



Interesting Case from our web site www.fairfield-vets.co.uk



"Cassie" - Golden Retriever with Bladder Stones



Cassie

Mr and Mrs Rollins brought Cassie, a Golden Retriever, to see me, because her lip was drooping on the left hand side. As a consequence she was salivating on that side.

This led me to believe that she was suffering from facial paralysis. I wanted to admit her for a full neurological examination to confirm this diagnosis.

However, when I did a full clinical examination and palpated her tummy, I came across another problem. Her bladder was enlarged and felt like a bag full of pebbles. I advised the owners, who had seen no symptoms at all, that I should investigate this further at the same time.

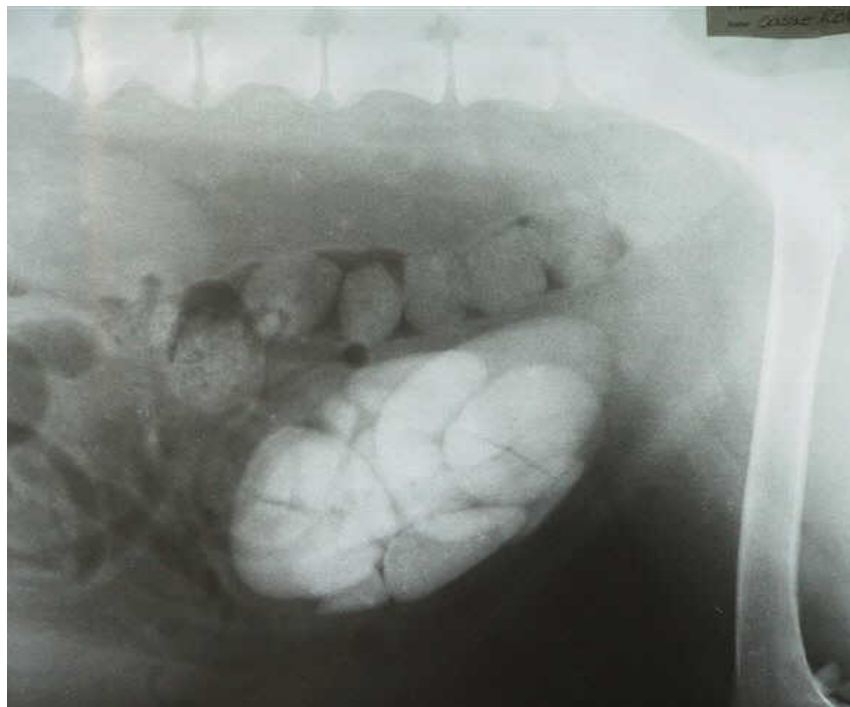
Cassie was admitted and a neurological examination was performed first, this indeed indicated that she had a paralysis of her facial nerve. She could not blink with her left eye and had no feeling on that side. The cause of this condition is often unknown, and improvement may take weeks or months.

An xray of her tummy confirmed that she had multiple bladder stones, and she was operated on a few days later.

To our surprise more than thirty stones varying from a few millimetres to 4 centimeters were removed from her bladder.

She is now making a full recovery from her operation, but we will need a little more time to see if how quickly her facial paralysis improves.

By Ingrid Segboer MRCVS



Cassie's X-ray.

Her bladder, full of stones, is the light area bottom centre.

Above that is her rectum with a chain of faeces visible.

Her spine can be seen across the top with her femur (thigh bone) on the right.

This article is available on the Fairfield Veterinary Centre web site at www.fairfield-vets.co.uk

You won't care how much we know - until you know how much we care